

## **Chop, Chop! Tips for Performing a Speedy Field Necropsy**

**Elizabeth R. Homerosky, DVM, MSc., DABVP (Beef Cattle Practice),  
Brian N. Warr, DVM, MSc.**

Veterinary Agri-Health Services Ltd.  
Rocky View Co., Alberta, T4B 4L5, Canada

### **Abstract**

Field necropsies provide important information regarding both individual animal and herd health. Adequate preparation, including following an agreed-upon plan with the producer, obtaining proper equipment, and collecting a thorough history, contributes significantly to successfully determining a diagnosis in a timely manner. Standard equipment includes proper outerwear, a necropsy knife, honing steel and an axe or reciprocating saw. Cattle should be placed left side down and prosected in a manner that allows the veterinarian to examine relevant organs in a consistent order. By developing a standard necropsy routine, the veterinarian is less likely to overlook organs with significant gross lesions. In the absence of distinctive gross lesions, submission of photographs or tissue samples to an experienced veterinarian or diagnostic laboratory may help with determination of the diagnosis or etiology.

### **Introduction**

Field necropsies provide important information regarding both individual animal and herd health. This information can be used to guide critical production decisions such as developing or refining preventive herd health and treatment protocols (Griffin, 2012). However, some veterinarians do not perform field necropsies on a regular basis. Possible reasons for not performing field necropsies include lack of perceived value by the client, confidence, competency, or promotion of services by the veterinarian. Additionally, lack of proficiency may result in client and veterinary concerns over time investment to perform a field necropsy. Whether we are considering animal body condition scores or personnel time and labor inputs, our goal as cow-calf and feedlot production veterinarians is often to “optimize”, rather than “maximize”. This philosophy also pertains to field necropsies.

Field necropsy techniques vary tremendously from the “gold standard” techniques utilized and taught in veterinary school. In the field, we strive to obtain as much valuable information as possible in a limited, but reasonable, amount of time. The objectives of this presentation are to familiarize students and new graduates with time-saving necropsy techniques that will allow them to “optimize” their time in the field and help them improve their overall confidence and competency by sharing tips and tricks for fine-tuning a comprehensive list of differential diagnoses. Ultimately, we hope the following information will help new graduates provide as much value as possible to their producers.

### **Preparation**

Agreeing upon a plan for both the producer and veterinarian can help make the necropsy event productive and efficient for both parties. This plan should include prompt reporting of deceased animals, especially during extreme hot or cold weather conditions. The producer should be readily able to provide specific information regarding the animal’s age, days on feed if

applicable, treatment and procedure history, clinical signs prior to death, location of death, number of pen mates or herd mates affected, and euthanasia technique if applicable. This information is critical for developing a comprehensive list of differential diagnoses, particularly in a disease outbreak investigation. A standardized form may help the veterinarian obtain a consistent history in a timely manner.

Producers should work with their veterinarian to determine a standard location for performing necropsies. This location should be isolated from live animals and in an inconspicuous area. In some situations, it may be important to examine the location of death and position of the animal before moving the animal to a more appropriate location. If the animal is still alive, videos captured by the producer or delaying euthanasia until an antemortem examination has been performed may also contribute to a comprehensive list of differential diagnoses. If clinical signs are consistent with neurologic disease and the brain is to be submitted for testing, euthanasia by gun shot or captive bolt should be avoided. Finally, the plan should include a method for carcass disposal compliant with local laws and regulations. Potential options include rendering, composting or burying.

### **Equipment**

Proper attire, a necropsy knife, honing steel and a tool for opening the thorax is all that is required to complete a field necropsy. Proper attire includes clean rubber boots and coveralls, rubber or latex gloves, and eye protection. Despite the fact we are dealing with deceased animals, proper biosecurity measures should be practiced as dirty boots and coveralls may serve as a vector for disease from operation-to-operation. Additionally, proper attire is necessary to portray cleanliness and professionalism.

The importance of having good quality, sharp knives cannot be overemphasized. Many types of knives are available on the market place and every veterinarian is encouraged to try different styles to determine what style is the most effective for them. Straight-backed, stainless steel knives that are minimum 15cm in length, are recommended by the authors. Knives should be adequately sharpened using a belt grinder, slate, stationary knife sharpener or other technique. True honing steels, more commonly and erroneously referred to as “sharpening steels”, do not sharpen the blade. Rather, they straighten the blade edge, and are a critical tool for maintaining the knife cutting edge when transecting any amount of hide, cartilage or other thick tissues. In the author’s experience, a sharpened axe or battery-operated reciprocating saw are the most effective tools for facilitating removal of the rib cage. A fair amount of practice is necessary to master the art of opening a thorax with an axe. The authors do not recommend the use of hedge trimmers due to the time and effort that is required, in addition to the limited durability and lifespan of these tools. In the absence of more specialized tools, a knife can be used to transect the costochondral junctions and tissues between each rib. Following this, the ribs can easily be reflected at the level of costovertebral joints by cutting between ribs and pulling each individual rib caudally toward the hip (not dorsally). This is only recommended on young animals due to the difficulty associated with transecting the costochondral junctions in mature animals and resulting damage sustained by your knife.



### **Necropsy Technique**



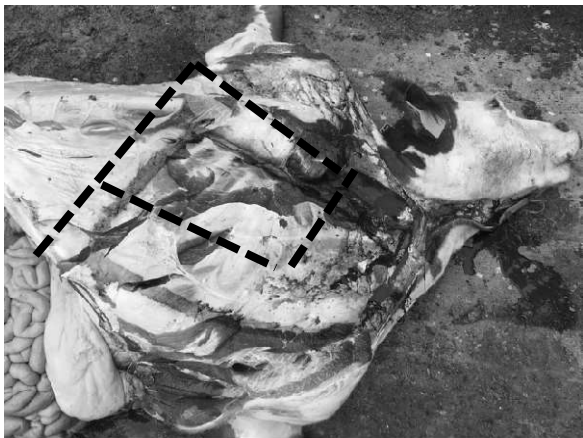
Each veterinarian develops their own field necropsy technique and routine over time. Consistent techniques among veterinarians are not nearly as important as consistent techniques between necropsies by the same veterinarian. The authors recommend students and new graduates observe as many field necropsies performed by as many veterinarians as possible before deciding which technique is the most practical and logical for them. It is imperative each necropsy is completed and organs are examined in a consistent order every time to minimize the risk of overlooking a lesion. In the words of Thomas McCrae, “More is missed by not looking, than not knowing.”


For the necropsy, the animal should be laid in left lateral recumbency. This facilitates thorough examination of the abdominal organs once the carcass is opened as the rumen obscures most of the intestines when the animal is placed in right lateral recumbency. A common rule used by the authors, is “right is wrong”. Once the animal is in the appropriate position, the animal should be examined from all sides, noting any abnormalities of the joints, claws, perineum, skin and hair, eyes, ears, oral cavity, udders and vulvas on females, testicles on bulls, castration sites on steers, and navels on neonatal calves. Tags and other forms of identification should also be noted as well as euthanasia technique, if applicable. If photographs are to be taken, the dangle tag with management identification number should be removed and placed in each view before taking a photograph. It is common practice to make a stab incision into the right or left paralumbar fossa in animals with a distended abdomen, however for some diseases and particularly neonatal calves, this is contraindicated.

In the authors’ experience, veterinary students and new graduates struggle most with reflecting the hind limb, opening the stifle, and opening the thorax. A general recommendation when reflecting the limbs is to cut wherever there appears to be tension or stretched tissue. The following represents a common approach among feedlot production veterinarians regarding carcass prosection (Table 1).

Table 1 – Recommendations for carcass prosection in a field setting.

Step	Technique	View
Opening the carcass	Cut a hands-width above midline from the submandibular area to the perineum	
Reflect the hind limb	Lift the hind limb, cutting through any areas of tension, open the	

	<p>coxo-femoral joint, and continue cutting along dotted line until the limb is fully reflected</p>	
<p>Opening the stifle</p>	<p>Cut in a “U” shape on the medial side of the stifle to open the joint</p>	
<p>Reflect the front limb</p>	<p>Lift the limb, cutting through fascia to reflect the limb</p>	
<p>Opening the thorax</p>	<p>Transect costo-chondral junctions of ribs ~2-8  Transect coinciding costo-vertebral joints  Cut caudal to the last free-floating rib extending through the ventral cartilage  Cut cranial to the most cranial free-floating rib and reflect the rib cage</p>	

<p>Presentation view</p>	<p>Cut through the abdominal wall following the curvature of the rib cage and reflect dorsally Transect the omentum</p>	
--------------------------	---	--

With the carcass in presentation view, all organs should be easily accessible by the veterinarian for further examination. It is recommended that the viscera are opened and examined last to minimize contamination and prevent ingesta from obscuring other organs. Organs commonly examined include, but are not limited to, the tongue, larynx, esophagus, trachea, lungs, pericardium, heart (left and right ventricles and papillary muscles, mitral and tricuspid valves), caudal vena cava, diaphragm, liver, kidneys, abomasum, rumen, ileum, cecum, spiral colon, lymph nodes, muscle and udder and uterus when applicable. The heart is easily removed by making a ~10cm transverse incision near the apex of the heart. This incision can be used as a hand-hold to facilitate exteriorization of the heart while the base is transected. The larynx, and cranial aspect of the trachea and esophagus are reflected for examination whereas the tongue is commonly left in place and examined through the oral cavity. There are several methods used to remove the brain. Use of an axe is highly recommended for field necropsies. The authors' technique closely aligns with those reported by Griffin (2012). In some cases, the renderer may not be able to remove an animal with an opened cranium. Special consideration should also be taken to have as few loose tissues and organs as possible. This will facilitate easy removal by a renderer and improve cleanliness of the necropsy site. Additionally, the hide is the single most valuable component of a rendered carcass. As such, unnecessary cuts through the hide should be avoided.

### **Considerations for Neonatal Calves**

Examination of the umbilical structures and additional joints are of utmost importance when performing necropsies on neonatal calves. Any abnormalities, especially swollen joints, should be further examined. The authors also recommend transecting the tongue to look for striations indicative of white muscle disease and closely examining the heart for septal defects.

Examination of aborted fetuses and stillborn calves is often unrewarding due to the frequent absence of gross lesions. Significant hemorrhage present within the umbilical arteries and successful flotation of lung tissue in water are excellent indicators that the calf was born alive. For calves born dead, the authors recommend the following indicators to estimate the amount of time between fetal death and birth. Calves with a cloudy appearance to their cornea

are estimated to have been dead for at least 6 hours before birth. Those with loose hair are estimated to be dead for at least 12 hours and emphysematous calves are estimated to be dead for at least 24 hours.

### **Considerations for Down or Neurologic Cattle**

Examination of downer cattle can also be frustrating. In the absence of gross lesions, the all-encompassing diagnosis of “neurologic disease” is sometimes a diagnosis of exclusion. There are very few neurologic diseases in feeder cattle that result in gross lesions. Cattle affected with histophilus or septicemia often have a combination of 2 or more of the following: fibrinous arthritis, pleuritis, pericarditis and peritonitis. Nervous-associated coccidiosis commonly spikes following extreme cold spells. These cattle have been noted to have edema present on the surface of the cecum and spiral colon and surrounding mesentery. For cattle with no obvious gross lesions, subcutaneous hemorrhage and edema, evidence of mud high on the hide and a full bladder are all key indicators that an animal was down for a prolonged period of time preceding death. Removal of the brain for diagnostic testing is often necessary to obtain a definitive diagnosis of polioencephalomalacia, meningitis, salt toxicity/water deprivation, listeria and rabies, among others. In contrast, metabolic disease such as calcium or magnesium deficiency, are very common causes of neurologic disease in the peri-parturient cow. Submission of vitreous humor to a diagnostic laboratory can be instrumental in confirming a cause of death for these types of cases. In cases of uncertainty, the authors highly recommend collecting fresh and fixed samples for possible submission at a later date.

### **Diagnostic Tips**

An animal’s signalment should be considered when formulating a list of possible differential diagnoses. However, in feedlot production medicine, information regarding days on feed provides the most valuable insight. Feedlot diseases are highly predictable and cluster based on time since entry to the feedlot (Figure 1).

There are a number of other published and unpublished observations commonly used by feedlot production veterinarians to help confirm a diagnosis. The following represent a few gross lesions commonly associated with different disease processes.

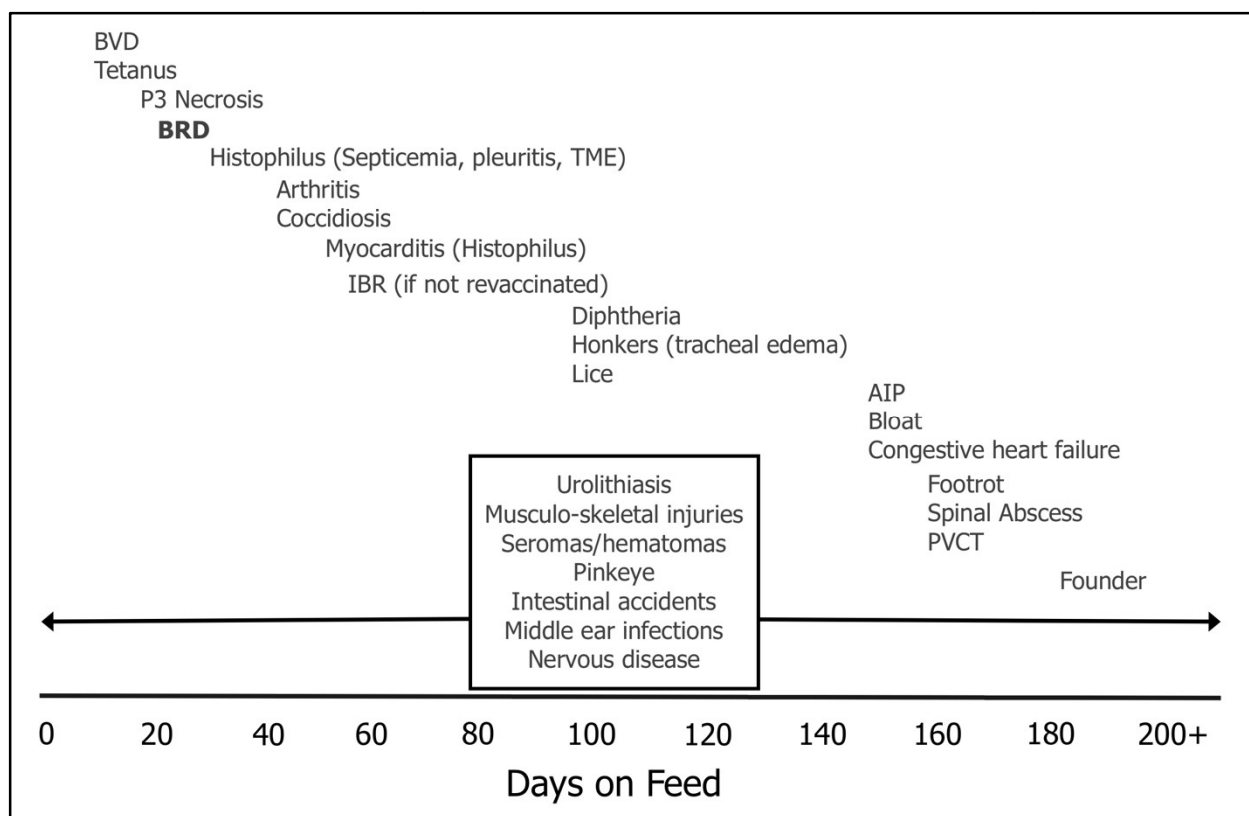


Figure 1 – Onset of common feedlot diseases based on days on feed (Figure courtesy of Veterinary Agri-Health Services, Ltd.)

Unclotted blood: Anthrax is often the primary differential diagnosis for animals with a large amount of unclotted blood. However, unclotted blood is a common clinical sign in feedlot animals with congestive heart failure. This is thought to result from disruption of the clotting cascade secondary to chronic passive congestion of the liver. Other causes of liver disease have also been observed to result in carcasses with unclotted blood. The presence of pulmonary edema is another key indicator of congestive heart failure or other type of cardiomyopathy.

Toe tip necrosis complications: in some cases, signs of toe tip necrosis on the exterior of the claw may be discreet. This disease usually peaks ~1-4 weeks after arrival at the feedlot and live cattle typically have a characteristic gait. At necropsy, gross lesions such as embolic pneumonia or cellulitis may be the predominating signs. The authors highly recommend carrying a pair of hoof trimmers and nipping toes to confirm toe tip necrosis is the initiating cause of these other complications.

Flocculent material in joint fluid: While flocculent material may be associated with septic arthritis, it is also a clinical sign the authors have observed to be associated with grain overload.

### Final Considerations

After the field necropsy has been completed and any samples or photographs have been collected, loose parts should be placed in the thorax to promote a clean necropsy site. The

carcass should be closed by returning the limbs to their original position. This facilitates easier removal and placement on the truck if the carcass is to be rendered.

### **Conclusion**

Field necropsies are a grossly underutilized tool that can provide valuable information regarding both individual animal and herd health. Whereas there is tremendous variation in technique between veterinarians, a consistency in methods by each individual is the key to successfully obtaining a diagnosis. The aforementioned tips and tricks are intended to assist students and new graduates in performing field necropsies in a timely manner and formulating a comprehensive list of differential diagnoses. Students and new graduates are encouraged to observe multiple veterinarians with varying techniques before adopting a standard necropsy routine.

### **References**

Griffin D. Field necropsy of cattle and diagnostic sample submission. 2012. *Vet Clin North Am Food AnimPract.* 28:391–405.